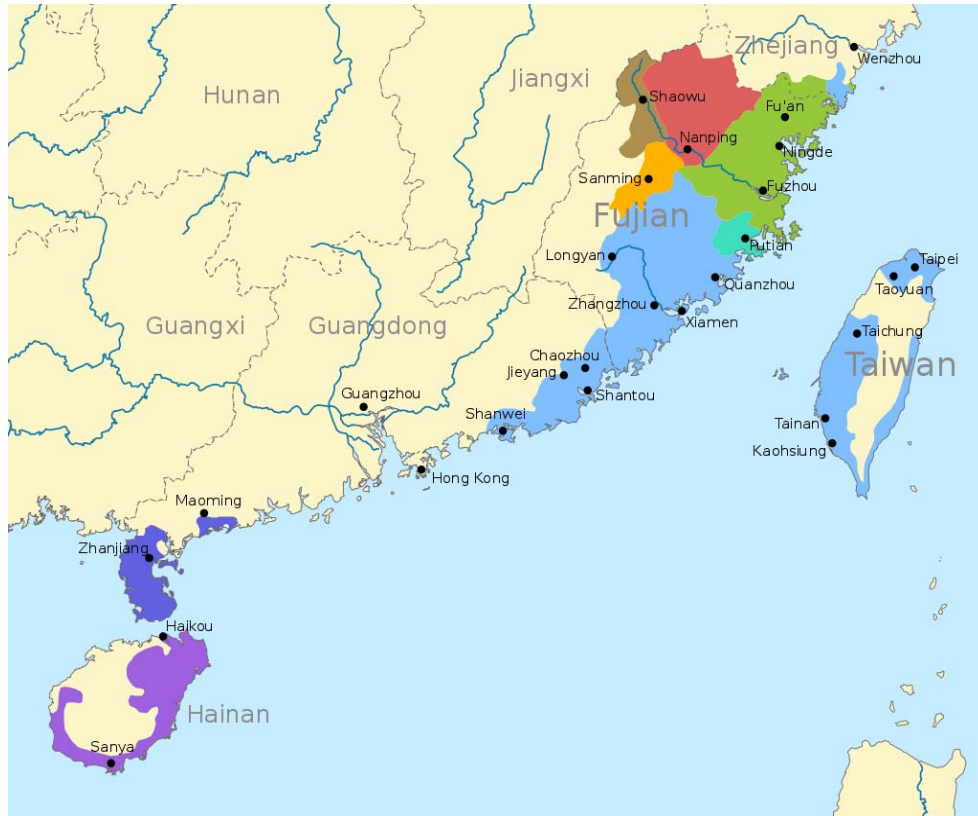
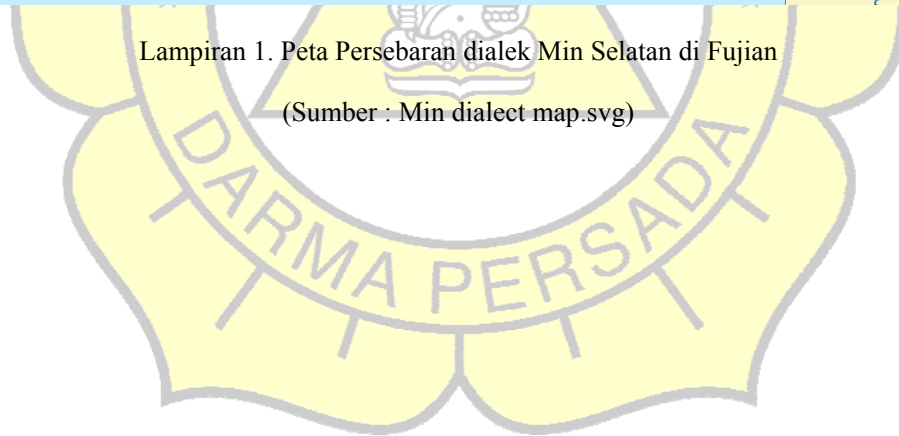


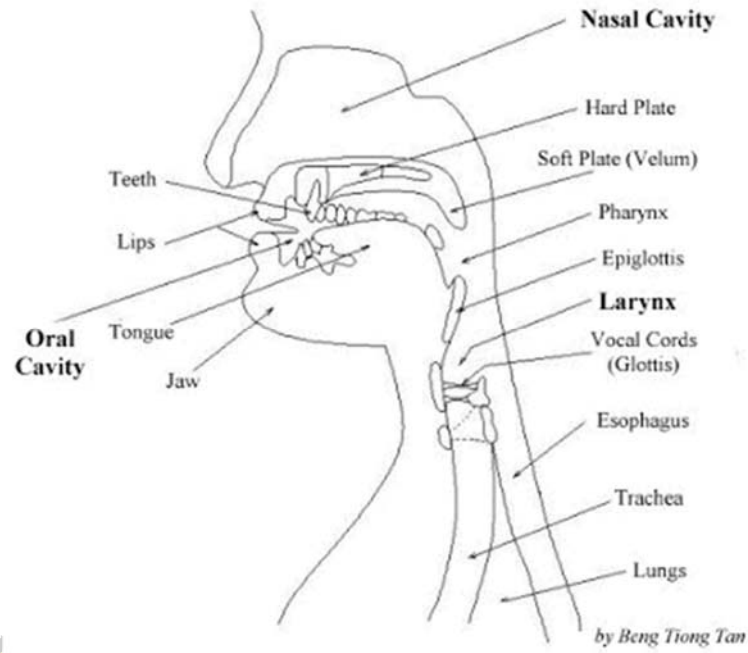
LAMPIRAN



Lampiran 1. Peta Persebaran dialek Min Selatan di Fujian


(Sumber : Min dialect map.svg)





Lampiran 2. Susunan organ tubuh untuk produksi bunyi bahasa

(Sumber : Crystal, 1993)



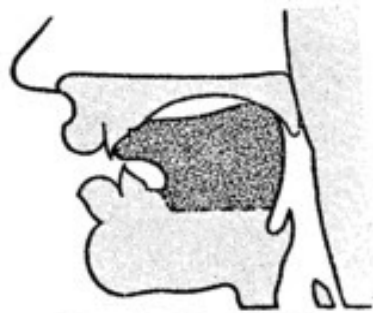


FIG. 42. Dental Click.

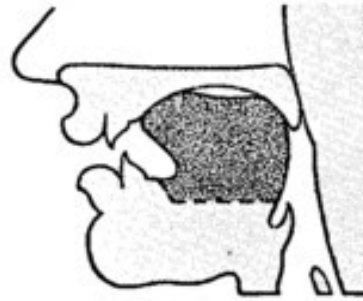
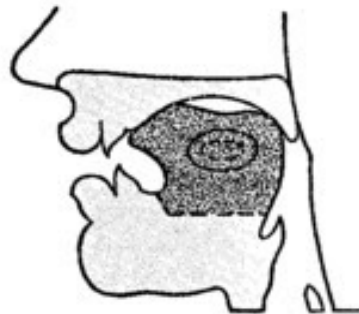


FIG. 43. Palato-alveolar Click.



Position of
Lateral Release

FIG. 44. Lateral Click.

Lampiran 3. Gambar pelafalan konsonan bunyi dental dan palatal

(Sumber : John Well's Phonetics)

